



Experience our dedicated Breast Imaging Services

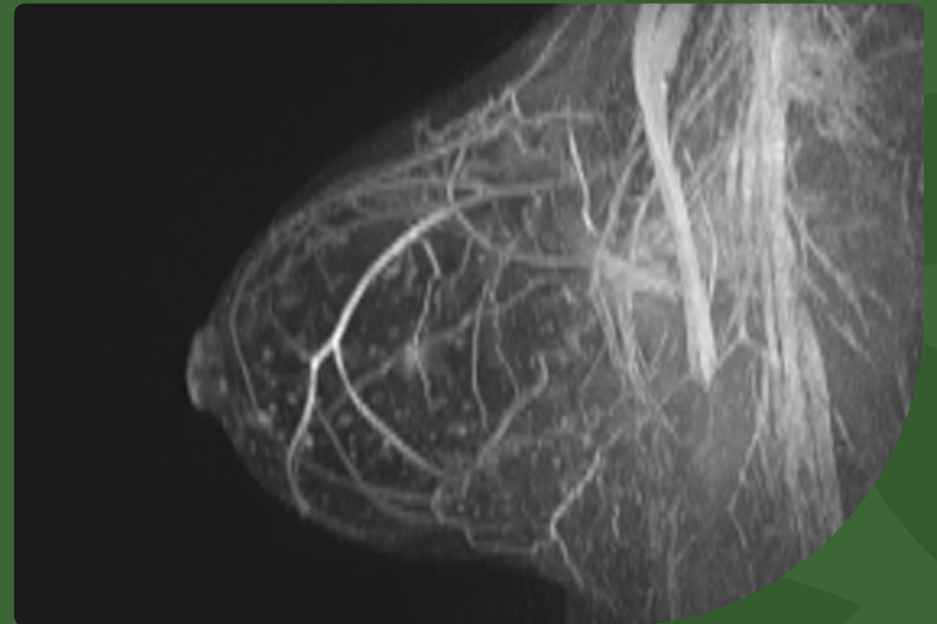
Providing patient centered excellence across the North Island

[Read more →](#)



Breast **MRI**

MRI provides detailed images of internal and soft tissue structures of the breast, which enables a range of diagnostic procedures including assessment of implants, high risk screening and more accurate staging and treatment planning.



Breast Density

Breast density refers to the makeup of breast tissue which can only be determined through a Mammogram. Breasts are made up of fibroglandular tissue and fatty tissue. When breasts have a lot of fibroglandular tissue, they can be judged as dense. A number of factors can affect breast density, such as age, menopausal status, the use of medications (such as menopausal hormone therapy), pregnancy and genetics.

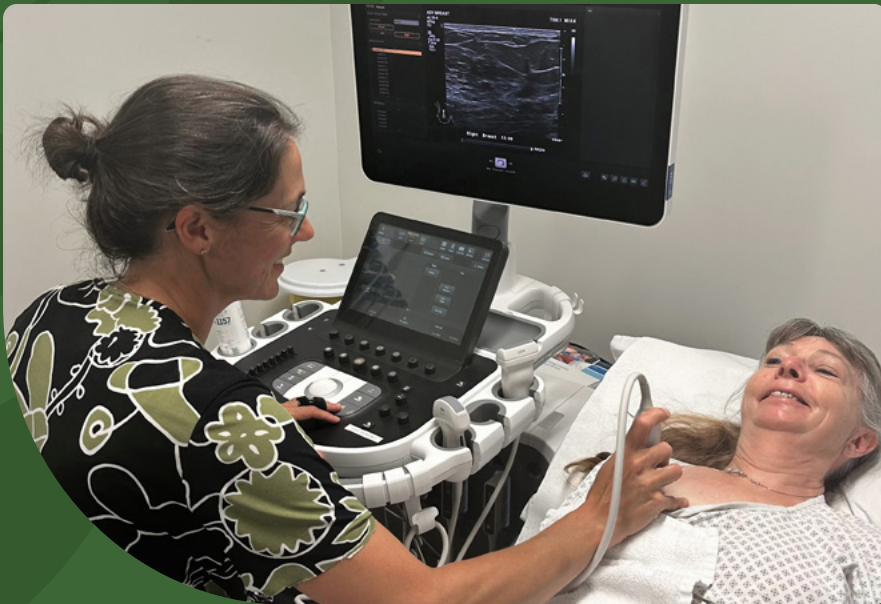Volumetric Breast Density scale

- Breast density is classified into four categories, A-D; with categories C and D considered dense
- We use the Internationally recognised breast density measurement tool Volpara to classify density
- Understanding breast density score enables a more personalised management approach to breast health, based on an individual's risk factors



Breast **Ultrasound**

Breast ultrasound does not use x-rays, instead using high-frequency sound waves to evaluate breast tissue. A breast ultrasound does not replace the need for a mammogram, but it is often used to help evaluate dense breasts or areas of interest identified on a mammogram.



“Breast cancer continues to have high mortality which makes us realise that screening mammography alone is not enough. It is well established that additional imaging is often required and breast screening should be personalised to adjust for individual risk. At Canopy Healthcare we offer breast ultrasound and tomosynthesis to significantly increase cancer detection rates.

We also offer breast MRI which is the most sensitive tool to detect breast cancer. Breast MRI is increasingly being used as a screening tool for higher risk women where mammography screening alone may miss their cancers. It has previously been underutilised but with our new Abbreviated MRI protocols and the latest equipment, we are able to make this more accessible to our high risk clients. There is no doubt that Breast MRI has lifesaving potential.

2024 will be an exciting year as we extend this technology to more of our clients.”

Dr Jeanie Jennings

Mammogram – 3D Tomosynthesis

A three-dimensional (3D) mammogram, also known as breast tomosynthesis, is a form of digital mammography in which many pictures of thin slices of the breast are taken to produce a 3D image. Our specialist radiologist reads this in conjunction with the state-of-the-art 2D digital images taken.

Our Mammography system enables the following:

- Wide angle tomosynthesis minimises tissue overlap that can hide carcinomas or make it difficult to distinguish overlapping breast tissue from tumours¹
- Advanced technology to reduce patient discomfort during the examination
- Stereotactic biopsy for assessment of microcalcifications (a tiny cluster of small calcium deposits) detected on mammography; or biopsy of non-palpable nodules also not visible on ultrasound





Canopy Imaging Whangarei

E appointments@canopyimaging.co.nz

P 09 437 0540

Auckland Breast Centre

E abc@aucklandbreastcentre.co.nz

P 09 488 9179

TRG/Canopy Imaging Rotorua

E rotorua@trgimaging.co.nz

P 07 348 8139

TRG/Canopy Imaging Taupo

E taupo@trgimaging.co.nz

P 07 377 3372

TRG/Canopy Imaging Hawke's Bay

E hawkesbay@trgimaging.co.nz

P 06 873 1166

TRG/Canopy Imaging Gisborne

E gisborne@trgimaging.co.nz

P 06 867 0736

Broadway Radiology

E brl@broadwayradiology.co.nz

P 0800 111 060

Providing patient centered excellence across the North Island

www.canopyimaging.co.nz

References

1 Zackrisson, S; Lang, K; Rosso, A; Johnson, K; Dustler, M; Fornvik et al, (2018) One-view breast tomosynthesis versus two-view mammography in the Malmö Breast Tomosynthesis Screening Trial (MBTST): a prospective, population-based, diagnostic accuracy study; *The Lancet*